

## Subacute Thyroiditis in the Setting of Coronavirus Disease 2019

To the Editor:

Coronavirus disease 2019 (COVID-19) is responsible for the ongoing global pandemic. Since it was discovered, COVID-19 presentation varies from a mild flu-like illness to multi-organ dysfunction such as acute respiratory distress syndrome, septic shock, and kidney failure.<sup>1,2</sup> However, there have been no cases to date that described the association between COVID-19 and subacute thyroiditis, commonly known as de Quervain's thyroiditis. We report a patient diagnosed with subacute thyroiditis after recovering from COVID-19 disease. Our goal is to alert clinicians about this new entity and recognize the symptoms of thyroid dysfunction, which could go unnoticed during the height of this pandemic.

A 37-year-old man presented to his primary care physician (PCP) office with a one-week history of anterior neck pain, fatigue, and chills. He denied any radiation of his neck pain, dysphagia, or active respiratory symptoms. A review of systems was positive for palpitation, heat intolerance, anorexia, and unintentional weight loss. Of note, he was recently diagnosed with COVID-19 about a month prior after presenting with flu-like illness involving productive cough, fever, chills, and dyspnea. He was self-quarantined at home, and his symptoms resolved after a week of supportive care. He reported that his current symptoms were different from what he experienced during his previous COVID-19 infection. He was healthy at baseline and denied taking any medications, including over-the-counter medicines and supplements. He worked as a physician specializing in pulmonary medicine. Vital signs revealed a regular heart rate of 100 beats per minute consistent with sinus tachycardia. He was afebrile and normotensive. Physical examination of his neck revealed a non-enlarged thyroid gland that is diffusely tender to palpation without any lymphadenopathy. No lid lag or lid retraction was found on ocular examination. Postural tremors were appreciated when his hands were raised forward in an outstretched position. His reflexes were brisk on examination. No muscle weakness or sensory abnormalities were found on the neuro exam. His hand exam revealed palmar erythema and was warm to touch. However, no evidence of any rash or edema found on examination of his other extremities. His laboratory findings were summarized in [Table 1](#). He had an outpatient thyroid gland ultrasound scan that revealed diffusely heterogeneous echotexture, which was concerning for thyroiditis ([Fig. 1](#)). His free thyroxine (T4) and total triiodothyronine (T3) levels were elevated at 2.3 ng/L and 202 ng/L, respectively. Thyroid-stimulating hormone (TSH) was low at 0.01 mU/L. Thyroid peroxidase antibody (TPO Ab.), thyroid-stimulating immunoglobulin

(TSI), and reverse-transcription polymerase chain reaction (RT-PCR) test for COVID-19 returned negative. COVID-19-associated subacute thyroiditis was diagnosed. He was started on oral aspirin for his neck pain together with propranolol for his tachycardia and tremors. His symptoms improved after a week. However, he returned to his PCP office three weeks later with new reports of fatigue, anorexia, weight gain, constipation, and puffiness of his face. Repeat laboratory workup shown in [Table 1](#) revealed a paradoxical increase in TSH of 15 mU/L, but free low T4 and total T3 at 0.1 ng/L and 10 ng/L, respectively. The diagnosis of hypothyroidism was made, and 1.6 mcg/kg/day of oral levothyroxine was started. Oral aspirin and propranolol were discontinued due to the resolution of neck pain and palpitations. After a few weeks of levothyroxine therapy, he reported improvement in his symptoms. His repeat thyroid function test on day 70 ([Table 1](#)) demonstrated slightly elevated TSH of 6 mU/L, but normal free T4 and total T3 at 0.8 ng/L and 145 ng/L, respectively. Oral levothyroxine was continued at the current dose for a total duration of six weeks. He will follow-up with his endocrinologist after to ensure that his hypothyroid state is not permanent, where levothyroxine will be discontinued, and thyroid function tests are repeated.

Subacute thyroiditis is a self-limited inflammatory disorder of the thyroid gland which is more prevalent in females than males (4 to 1 ratio) and most often occurs at 40 to 50 years of age.<sup>3–5</sup> Subacute thyroiditis can occur during an active viral infection or post-viral inflammatory process in the setting of recent viral infections that occur two to eight weeks prior.<sup>3,5</sup> Viral infections that have been associated are coxsackievirus, mumps, measles, rubella, adenovirus, influenza, parvovirus B19, and many others.<sup>5</sup> Symptoms of thyrotoxicosis such as sore throat, fatigue, chills, anorexia, and weight loss can be easily confused for COVID-19 symptoms.<sup>2</sup> Therefore, a high clinical suspicion is required to rule out both diseases simultaneously. Up to 95% of patients will complain of thyroid-related pain, but its absence does not exclude the disease. Goiter may be appreciated in one-half of cases.<sup>4</sup>

Previous studies have shown that subacute thyroiditis occurs as the result of macrophages and cytotoxic T-cell recognition towards novel antigens that are either viral in origin or viral-induced host tissue damage. Thyroid follicular cell destruction will follow as they share the same structural similarity with these novel antigens.<sup>3,5</sup> However, the thyroid organ has been demonstrated to contain a significant amount of angiotensin-converting enzyme 2 (ACE2) receptor, which is essential for COVID-19 to invade human

**TABLE 1.** Laboratory results of test done on day of COVID-19 diagnosis until day 70.

Laboratory Finding	Day of COVID-19 Diagnosis	Day 30	Day 50	Day 70	Reference Range
WBC (10 <sup>3</sup> /uL)	6.4	6.7	6.5	N/A	4 to 9
Hemoglobin (g/dL)	14	13.8	13.5	N/A	13.5 to 16
MCV (fL)	86	85	90	N/A	80 to 95
Platelet (10 <sup>3</sup> /uL)	197	258	300	N/A	150 to 350
ESR (mm/hr)	50	31	20	N/A	0 to 15
CRP (mg/L)	20	14	5	N/A	<8
TSH (mU/L)	0.9	0.01	15	6	0.4 to 4.5
Free T4 (ng/dL)	N/A	2.3	0.1	0.8	0.6 to 1.3
Total T3 (ng/dL)	N/A	202	10	145	80 to 150
TPO Ab. (IU/L)	N/A	1	1	1	<9
TSI (IU/L)	N/A	0.1	0.15	0.1	0 to 0.55
RT-PCR COVID-19	Positive	Negative	Negative	N/A	

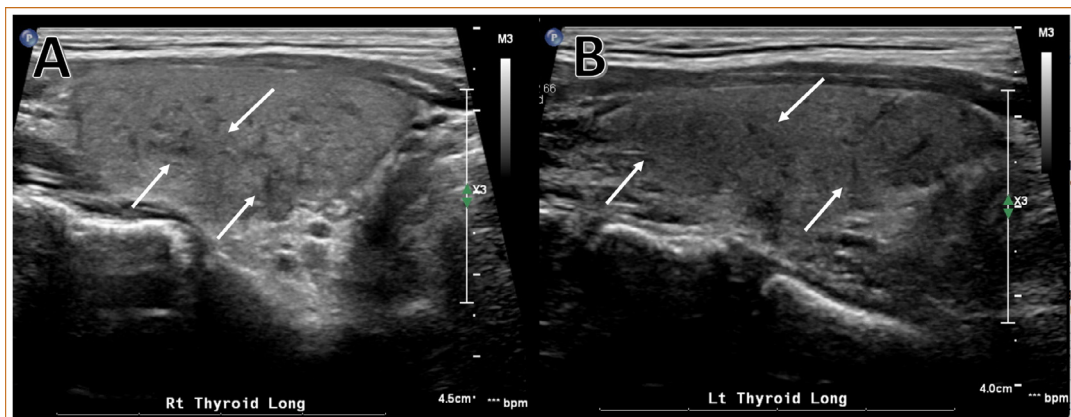
*Abbreviations:* WBC = white blood cell count, MCV = mean corpuscular volume, ESR = erythrocyte sedimentation rate, CRP = C-reactive protein, TSH = thyroid-stimulating hormone, T4 = thyroxine, T3 = triiodothyronine, TPO Ab. = Thyroid peroxidase antibody, TSI = thyroid-stimulating immunoglobulin, RT-PCR = reverse-transcription polymerase chain reaction.

cells.<sup>1</sup> A study by Li and colleagues suggested that males infected with COVID-19 had a higher amount of cytotoxic T-cell, natural killer cell, B cell, and interferon response in their thyroid when compared to females.<sup>1</sup> This finding could explain how our male patient was at risk of developing subacute thyroiditis. Thyroid auto-immunity does not play a role based on negative laboratory TPO and TSI antibodies.

Hyperthyroidism occurs during the initial phase of subacute thyroiditis from the release of intracellular preformed thyroid hormones in large amounts by the damage thyroid follicles. The damage thyroid follicles will not synthesize new thyroid hormones, and TSH secretion is inhibited through negative feedback mechanisms. Hyperthyroidism may evolve into hypothyroidism from the depletion of thyroid hormones in up to 60% of cases.<sup>4</sup> As the inflammation subsides, regeneration of thyroid follicles and thyroid hormone synthesis will occur, which signifies the recovery phase of subacute thyroiditis. Therefore, transitioning back to the state of

euthyroidism occurs and this entire phase may last anywhere between one to six months.<sup>3</sup>

Supportive care remains the cornerstone of treatment for COVID-19-associated subacute thyroiditis, where NSAIDs and beta-blocker of propranolol are useful for symptomatic management.<sup>3,4</sup> In some cases, patients may need a short course of levothyroxine during the hypothyroid phase if symptoms are severe until thyroid follicles resume thyroid hormone secretions. Anti-thyroid hormones are not required as this disorder originates from the release of preformed thyroid hormones instead of new thyroid hormone synthesis.<sup>3</sup> As this is the only case reported so far in the literature, further studies need to be done to support the hypothesis that the thyroid gland disorder could be well included in the cluster of COVID-19 clinical complications. Therefore, clinicians should keep this complication in mind when assessing patients and not misattribute thyroiditis symptoms towards pharyngitis or deconditioning that is often present during COVID-19 infection.



**FIGURE 1.** Thyroid ultrasound longitudinal view revealed that the thyroid gland was normal in size involving right lobe (A), left lobe (B), and isthmus. Thyroid gland echotexture is diffusely heterogeneous (white arrow) concerning for thyroiditis.

**Woon H. Chong,<sup>1,\*</sup>**  
**Boris Shkolnik,<sup>2</sup>**  
**Biplab Saha,<sup>2</sup>**  
**Scott Beegle<sup>1</sup>**

<sup>1</sup>Department of Pulmonary and Critical Care Medicine;  
Albany Medical Center, Albany, New York, USA

<sup>2</sup>Department of Pulmonary and Critical Care;  
Ozarks Medical Center, West Plains,  
Missouri, USA

E-mail addresses: [chongw@amc.edu](mailto:chongw@amc.edu), [Shkolnb@amc.edu](mailto:Shkolnb@amc.edu),  
[BeegleS@amc.edu](mailto:BeegleS@amc.edu)

Declaration of Conflicting Interests: The author(s) declare(s) no  
potential conflicts of interest with respect to the research,  
authorship, and/or publication of this article.

Funding: The author(s) received no financial support for the  
research, authorship, and/or publication of this article.

Author Contribution: All authors contributed to the writing and  
inception of this manuscript and had access to the data. Drs. Chong  
and Shkolnik are the guarantor of the article and take responsibility

for the integrity of the work, from inception to published article. Drs.  
Saha and Beegle helped with the revision and supervision of the  
manuscript.

## REFERENCES

1. **Li M-Y, Li L, Zhang Y, Wang X-S.** Expression of the SARS-CoV-2 cell receptor gene ACE2 in a wide variety of human tissues. *Infect Dis Poverty.* 2020;9(1):45.
2. **Guan W, Ni Z, Hu Y, et al.** Clinical characteristics of coronavirus disease 2019 in China. *N Engl J Med.* 2020;382(18):1708–1720.
3. **Bindra A, Braunstein GD.** Thyroiditis. *Am Fam Phys.* 2006;73(10):1769–1776.
4. **Fatourechi V, Aniszewski JP, Fatourechi GZE, Atkinson EJ, Jacobsen SJ.** Clinical features and outcome of subacute thyroiditis in an incidence cohort: Olmsted county, Minnesota, study. *J Clin Endocrinol Metab.* 2003;88(5):2100–2105.
5. **Desailly R, Hober D.** Viruses and thyroiditis: an update. *Virology.* 2009;6:5.